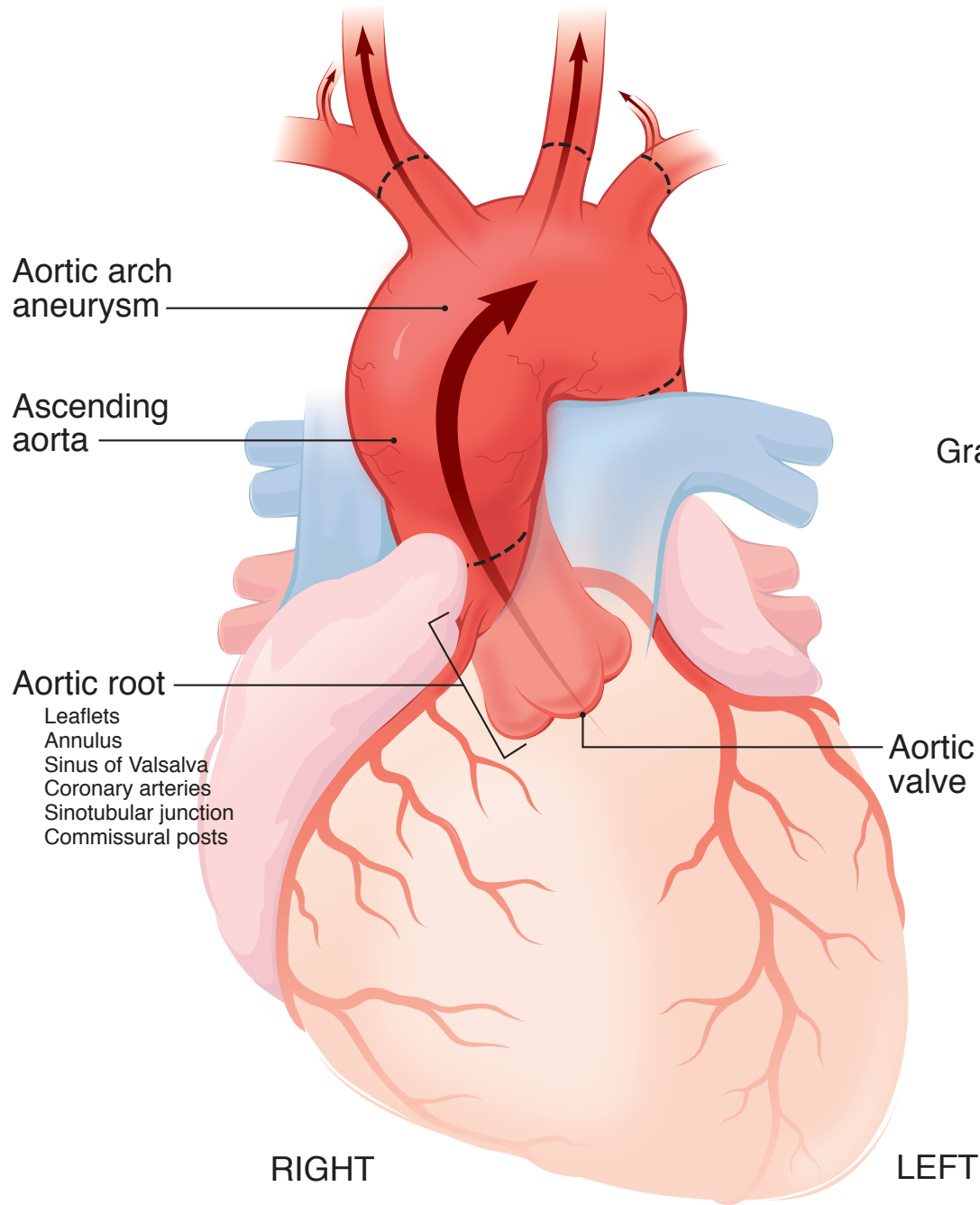
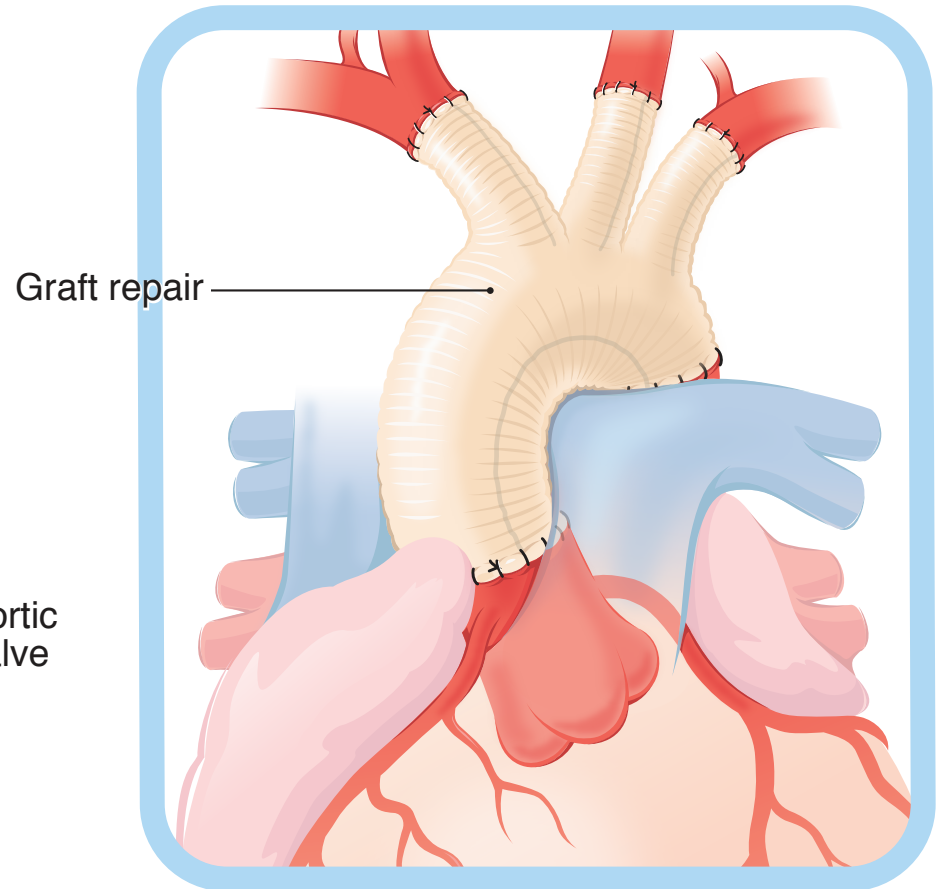


Aortic Arch Aneurysm



After Surgery



L.GAVULIC